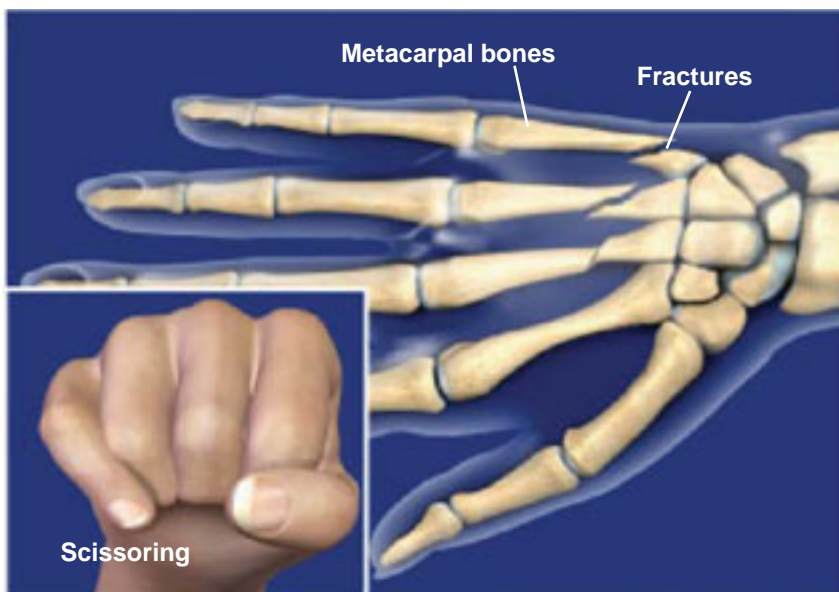


## FRACTURES OF THE HAND (METACARPAL FRACTURES)



### Overview

This condition is a fracture, or break, of one or more of the metacarpal bones of the hand. The fracture may be nondisplaced, in which the bones remain aligned, or displaced, in which the fractured ends shift out of alignment. Without proper treatment, the bones may not heal correctly. This can result in improper alignment of the fingers, leading to poor hand function.

### Causes

This type of injury is most often caused by direct trauma to the hand. Punching another object, a sharp blow to the hand, a fall, or a twisting or crushing injury can all cause a metacarpal hand fracture. A common scenario is a young male injuring the metacarpal of the little finger during a fight. If the break occurs at end of the bone nearest the knuckle, this is called a boxer's fracture.

### Symptoms

Symptoms typically include pain, swelling, and tenderness involving the broken metacarpal. Additional symptoms may include bruising on the back of the hand and in the palm, a bump on the back of the hand, and an overlap, or scissoring, of the fingers when making a fist.

### Treatment

The most common form of treatment is placing the hand in a cast while the bones heal. The fingers may also be taped together to prevent rotation of the fracture in the cast. If the fractured ends are misaligned, the physician may perform a closed reduction, in which the bones are pushed back into their proper positions. If the bones cannot be acceptably realigned with this technique, or if there is scissoring of the fingers, surgery will likely be required.

